

## Near Physiological Expansion A Step to Improve the Results of Tissue Expanders

ASSEM H. KAMEL, M.D.

The Department of Plastic & Reconstructive Surgery, Assiut University Hospital, Assiut, Egypt.

### ABSTRACT

The development of tissue expansion has added another technique to the armamentarium of the reconstructive surgery for management of defects that cannot be closed primarily without undue tension. There were some drawbacks pushed the researchers to try minimizing it.

*Patients and Methods:* Our technique of expansion "Near Physiological Expansion" was carried out for 34 patients admitted to the Plast. and Reconstr. Surg. Department - Assiut University Hospital, and Insurance Hospital of Assiut - Egypt within the period from JAN 2001 until, JAN 2004. We started inflation on the second post-operative day, inflation volume per time was calculated by equation and the inflation was done in divided doses, daily, at home.

*Results and Conclusions:* Were encouraging, as it allows easy, gradual, painless expansion, with continuous extrusion of the serum. It allows continuous change of the pressure points of the expander over the skin with subsequent prevention of skin erosion. Also, there was minimal capsular formation due to continuous expansion. The domestic inflation was not associated with any complication and follow up by telephone was applicable. Usually there were two visits between two surgeries.

### INTRODUCTION

The observation that living tissues respond, in dynamic fashion to mechanical forces placed upon them, has been applied to the clinical problem of surgical defects [1]. Since 1976 tissue expansion considered as a relatively straight forward procedure that enable the body to "grow" extra skin for use in reconstructing almost any part of the body [2].

Expansion offers a near perfect match of color, texture, and hair bearing qualities. The skin remains connected to the donor area's blood and nerve supply. In addition, because the skin does not have to be moved from one to another, scars are often less apparent [3].

Skin expansion has the following draw back, the length of time required to grow additional skin, tissue expansion can take as long as three or four

months. Furthermore, the procedure requires repeated visits to the surgeon for injection of saline that inflates the balloon [4].

*There were Four Techniques of Tissue Expansion were Described in the Literature:* 1- Slow (Traditional) method: Inflation started 2 weeks after implantation, inflation done twice weekly, for 4-8 weeks. 2- Rapid method: Started after 2 weeks, inflation done twice per week for 4 weeks, followed by maintaining period 2-4 weeks to prevent stretch back of the expanded flap. 3- Continuous method: It was carried out by restricting persistently the pressure in the expander near the pain threshold in a state of dynamic equilibrium between the infusion rate and the skin expansion velocity with special device. The inflation is fulfilled in 5 to 20 days. And, 4- Intra-operative expansion [5].

Complication rate in the literature range from 5-60% and decreases with operator experience. These included exposure, erosion, infection, rupture, perforation, hematoma, seroma, migration, pain, neuropraxia, and erosion or deformation of underlying bone [4,6,7].

### PATIENT AND METHOD

We started this method since Jan 2001 until, Jan 2004 in Plastic and Reconstructive Surgery Department, Assiut University Hospital and Insurance Hospital, Assiut-Egypt. The study included 34 patients; their ages ranged from 5-50 years (average 20.3 ys  $\pm$ 5.2). 16 were males and 18 females. The indications were tabulated in Table (1).

Table (1): Indications for tissue expansion.

Etiology	No.
Burn	32
Infection	1
Trauma	1

The anatomic sites were: Scalp 15 cases, face and neck 12 cases, upper limbs 2 cases, lower limbs 2 cases, chest and abdomen 3 cases (Table 2).

Table (2): Distribution of the anatomical sites.

Anatomical sites	Scalp	Face & Neck	Extremities	Abdomen
Total	34	15	12	4

The types of expander were rectangular in 27 patients, croissant in 5 patients, round in one patient and sausage shape in one patient. The incision which was done to introduce the expander either 1- Type I (20 cases): Placed within the scar tissue rather than normal skin and it was placed radially perpendicular on the junctional line between the scar and healthy skin, 2- Type II (14 patients): The incision lies transverse along the junctional line (Fig. 1). The dissected pocket should be larger than the width of the expander base by about 2cm. The filling port was placed away from the expander and leave it externally. We inflate the expander intra-operatively to allow its unfolding without induction any tension on the suture line.

*Inflation was started on the second post-operative day, three times per day as following:*

- 1<sup>st</sup> week, inject 10% of the suggested inflation volume.
- 2<sup>nd</sup> week, inject 30% of the suggested inflation volume.
- 3<sup>rd</sup> week, inject 40% of the suggested inflation volume.
- 4<sup>th</sup> week, inject 20% of the suggested inflation volume.

*The amount of fluid injected per time can be calculated as following:*

1 <sup>st</sup> w	$\frac{10\% \text{ the suggested inflation volume}}{7 \text{ days} \times 3}$
2 <sup>nd</sup> w	$\frac{30\% \text{ the suggested inflation volume}}{7 \text{ days} \times 3}$
3 <sup>rd</sup> w	$\frac{40\% \text{ the suggested inflation volume}}{7 \text{ days} \times 3}$
4 <sup>th</sup> w	$\frac{20\% \text{ the suggested inflation volume}}{7 \text{ days} \times 3}$

We divided the daily-suggested amount into three equal amounts, to be given three times per day, at home, after training the patients or his relatives and follow up was by telephone. The

expander removed immediately at the end of the 4<sup>th</sup> week. Before extraction of the expander, we overinflate it intra-operatively, with respectation of the skin condition.

## RESULTS

The study included patients of equal sexes; they were at different age groups. The commonest indication was post burn deformities 32 patients (Scarring and/or sicutricular alopecia). 2 out of the 34 patients on study presented by post infection or traumatic scarring. Head and neck region was the commonest anatomical site (27 patients), 15 patients had alopecia scalp, and 12 had post burn scarring in the face and neck.

Table (3): Complications in relation to the site, etiology and onset.

Complication	Patients number	Site of implantation	Indication	Onset
Wound dehiscence	2 Patients	Neck	Post burn deformity	4 <sup>th</sup> Week
Wound dehiscence	1 Patient	Scalp	Post burn deformity	4 <sup>th</sup> Week
Skin erosion	1 Patient	Scalp	Post infective deformity	4 <sup>th</sup> Week

Type I incision was carried out mostly in the scalp and extremities, within the scar. Type II incision was done in the face and neck.

We did not face any problem from inflation at home. Follow up by telephone was easy.

Follow up of our patients within the period of expansion revealed that the total incidence of complications was 12% (4 out of 34 patients on study). There were 3 patients developed wound dehiscence; they had post burn deformity in the neck in 2 patients, and the scalp in the third. The exposure line was type I in all patients. Dehiscence developed within the fourth week in the three patients. Manifestations of inflammation were detected in the three patients (Table 3).

One (3%) out of the 34 patients on study developed skin erosion, the exposure incision was type II, the expander was applied for a child with post infective alopecia scalp secondary to haematoma after forceps delivery. Erosion manifest within the fourth week, and without significant inflammatory reactions (Table 3).

The target inflation volume was achieved in all patients, no definite capsule was detected, and there were good skin elasticity.

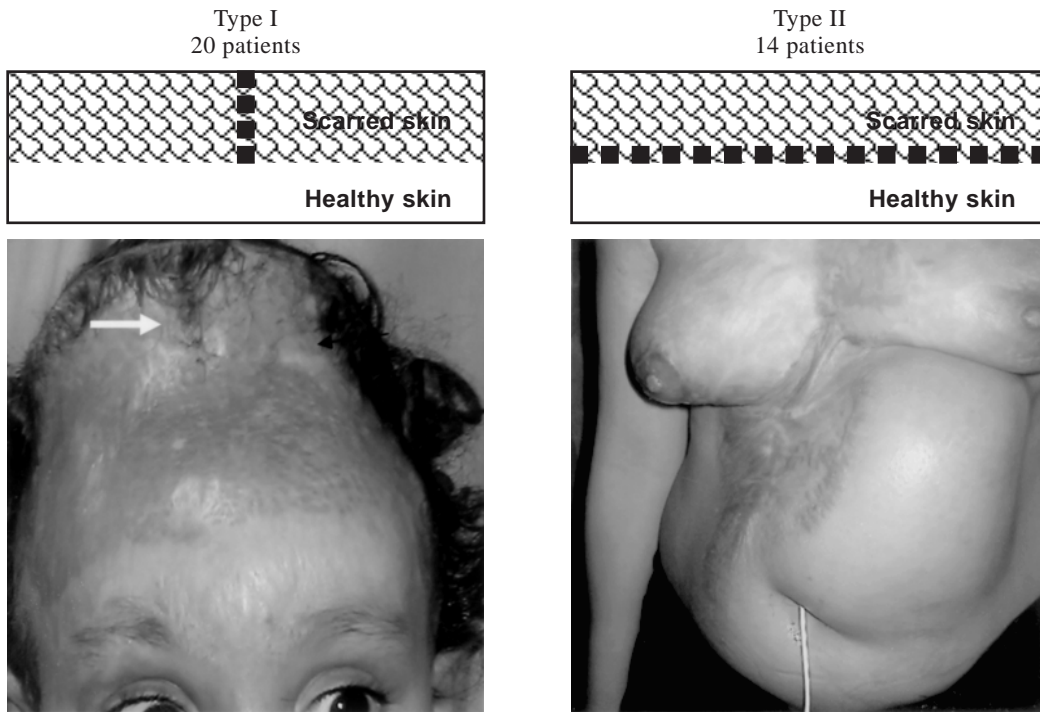


Fig. (1): The incision for introduction of the expander. Type I through the scarred skin, perpendicular on the junctional line between the healthy and the scarred skin. Type II through the junctional line between healthy and scarred skin.

Fig. (2): Expanded suture line.

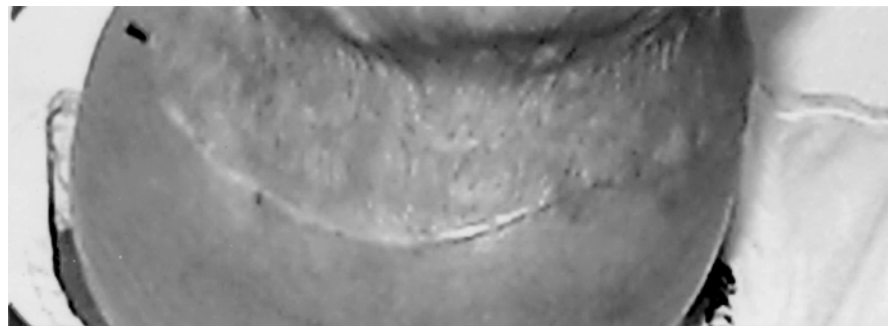

Fig. (3): Pressure points which were weak points for skin erosions.

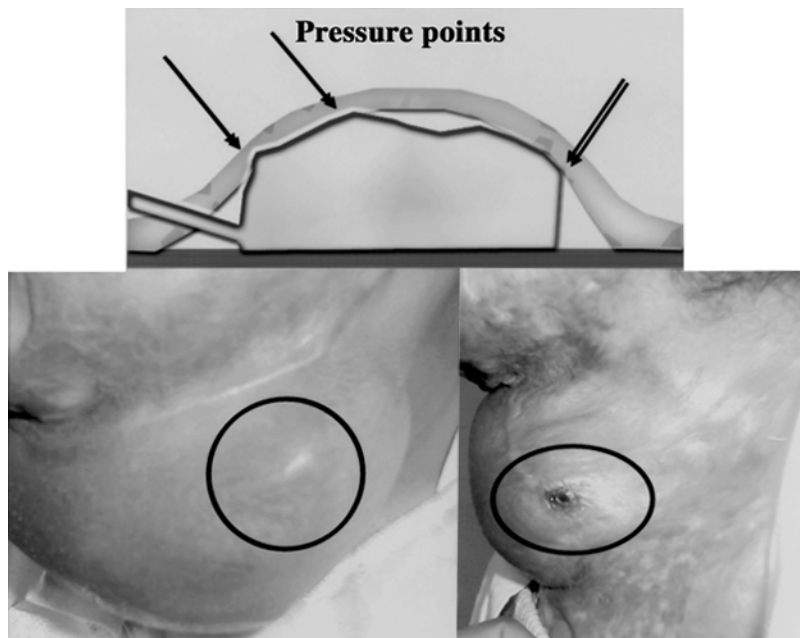
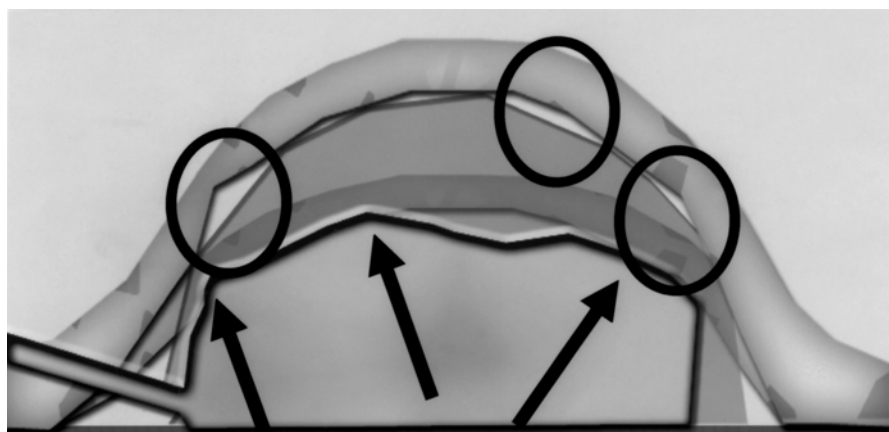


Fig. (4): Pressure points continuously change by near physiological expansion.



## DISCUSSION

The idea of skin expansion solves many problems in reconstructive surgery. However, there are some drawbacks such as, frequent office visits for inflation, discomfort, and a period of increased deformity during the time of inflation. In the pediatric population, emotional disturbances may accompany the use of tissue expanders. Formation of a capsule may result in reduced skin elasticity, and impeded flap movement and the expanded skin has a tendency for postoperative retraction [8]. Seroma, haematoma, infection, erosion, and disruption, are the common complications mentioned in the literature with a variable incidence ranged from 15.5 to 25% [4,6]. All are represented in the theatre of research to improve the results.

The suggestion of “near physiologic expansion” was expansion by very gradual inflation. These will minimize fibrous tissue formation (i.e. capsule) as documented by expansion of the suture line itself (Fig. 2). It shortens the period of expansion (4 weeks), unlike the traditional method, and without the need for maintaining period as in case of rapid expansion. Daily inflation in divided doses allowed continuous extrusion of the exudates and prevents its collection between the folds of the expander or in the pocket, through the external port of the inflation valve, that is why; there was neither haematoma nor seroma detected in patients on study. These also minimize infection markedly. The incidence of seroma in the previous reports was up to 8% [4]. Near physiologic expansion was cost effective if compared to the continuous method, which needs a special device that described, by Argenta et al. [9].

The mechanism of erosion was described to be due to pressure necrosis at the site of expander corners (Fig. 3) or the tip of expander folds [5]. Many companies tried to minimize this sequel by

manufacturing the expander with curved corners. The process of daily inflation on divided amounts (Near Physiological Expansion) allows continuous change of pressure point over the skin every 8hrs, this idea helps to minimize skin erosion (Fig. 4). However, in patients presented with post infective and traumatic alopecia, there were fibrosis of the underlying surface of the surrounding hairy scalp, this fibrosis resulted in loss of scalp elasticity and makes its inflation difficult. This may explain the erosion that occurred in this study.

The “Near Physiological Expansion” was not associated with pain as described with other modalities [10], this advantage was highly significant especially in children.

We agree with the study of Mohmand, et al. [11] that the practice of inflation at home was safe, cost effective, and less stressful for the patients. Follow up through the telephone reduce the number of visits.

### Conclusions:

Near physiologic expansion was good and reliable method. It allowed continuous extrusion of serum from the pocket of the expander; it minimized the incidence of skin erosion during expansion and capsular formation. The process of expansion was pain free. The domestic inflation with follow up by telephone was applicable and was not associated with any complication. There will be two visits between two surgeries.

## REFERENCES

- 1- Aslan G., Tuncali D. and Bingul F.: Are new designs in expander technology possible in order to minimize complications?. *Plast. Reconstr. Surg.* Oct., 112 (5): 1506-7, 2003.
- 2- Radovan C.: Tissue expansion soft tissue reconstruction. *Plast. Reconstr. Surg.*, 74: 482, 1984.

- 3- Johnson G.R., Han P. and Giacobelli J.A.: Tissue expansion as an alternative to skin grafting for closure of skin deficits. *J. Am. Pediatric Med. Assoc.* May, 82 (5): 249-59, 1992.
- 4- Cunha M.S., Nakamoto H.A., Herson M.R., Faes J.C., Gemperli R. and Ferreira M.C.: Tissue expander complications in plastic surgery: A 10-year experience. *Rev. Hosp. Clin. Fac. Med. Sao Paulo.* May-Jun., 57 (3): 93-7, 2002.
- 5- Don R. Revis: Tissue expansion. May, 18, 2002.
- 6- Yossef Saleh M.D.: Scalp reconstruction using tissue expander. *Egypt, J. Plast. Reconstr. Surg.*, Vol. 28, No. 1, January: 71-75, 2004.
- 7- Friedman R.M., Ingram A.E.Jr., Rohrich R.J., Byrd H.S., Hodges P.L., Burns A.J. and Hobar P.C.: Risk factors for complications in pediatric tissue expansion. *Plast. Reconstr. Surg.* Dec., 98 (7): 1242-6, 1996.
- 8- Chun J.T. and Rohrich R.J.: Versatility of tissue expansion in head and neck burn reconstruction. *Ann. Plast. Surg.*, 41: 11-16, 1998.
- 9- Argenta L.C., Marks M.W. and Pasyk K.A.: Advances in tissue expansion. *Clin. Plast. Surg.*, 12: 159, 1985.
- 10- Cole R.P., Gault D.T., Mayou B.J. and Davis P.K.: Pain and forehead expansion. *Br. J. Plast. Surg.* Jan., 44 (1): 41-3, 1991.
- 11- Mohmand M.H., Sterne G.D. and Gowar J.P.: Home inflation of tissue expanders: A safe and reliable alternate. *Br. J. Plast. Surg.* Oct., 54 (7): 610-4, 2001.